

**Title: THE REDUCIBILITY OF IDIOPATHIC SCOLIOSIS DURING NON-OPERATIVE TREATMENT.**

**Authors:** Christine Coillard  
Michel A. Leroux  
Karl F. Zabjek  
Charles H. Rivard

**Surgery Department, Faculty of Medicine, University of Montreal  
Research centre, Saint-Justine Hospital, Montreal**

**Correspondence:** Christine Coillard, M.D.  
Centre de recherche  
Hôpital Sainte-Justine  
3175 ch. Côte Ste-Catherine  
Montréal, Québec, Canada  
H3T 1C5

**Telephone:** (514) 345-4796  
**Fax:** (513) 345-4723

**Rubric: Original articles**

## **The Reducibility of Idiopathic Scoliosis during Non-operative Treatment.**

### **Summary:**

Non-operative treatment of idiopathic scoliosis is long and difficult. For the patient and the therapist it is particularly important to define early the therapeutic prognosis. The goal of this study is to verify if the initial reducibility at the beginning of the treatment with the dynamic corrective brace (SpineCor) would be valid as a prognostic factor, allowing a more effective prognostic judgement of the final outcome of the treatment.

This is a prospective study which includes 99 scoliosis patients (88 female, 11 male), with a mean age of 12.6 years, treated by the dynamic corrective brace for progressive idiopathic scoliosis curves (mean Cobb angle 29°). The initial Cobb angle was compared to the pre-therapeutic Cobb angle. The results demonstrate that the reducibility of the scoliotic curves with the brace at the beginning of treatment provides a significant global prognostic index but is difficult to apply individually. Other factors should be considered, such as the impact of growth velocity on the spinal deformity at the onset of the adolescent growth spurt as well as vertebral deformities around the apex at the time of the diagnosis.

Key Words: Idiopathic Scoliosis, Orthopaedic Treatment, Orthosis, Prognosis, Reducibility.

## **INTRODUCTION**

The brace treatment of idiopathic scoliosis has been considered alternately a therapeutic panacea, or excessive and disappointing, until being properly fitted in the range of the options of treatment (1, 2, 3). Still, a lot of questions have not been answered. In particular, it is always difficult to convince the patient in the necessity of the long and relatively burdensome treatment without being able to guarantee or at least define the outcome. In other terms, how to provide a valid therapeutic prognosis in the context of a pathology with unidentified cause and for which the long term prognosis with or without treatment rests imprecise when applied individually? The possibility to estimate the long-term efficiency of the treatment at the beginning would prevent in particular the patient and doctor's frustration, that occurs after a prolonged treatment of 2 to 4 years', when an operation is finally opted for.

In practice, it is always encouraging to observe a significant reduction of the curves at the x-ray control with the brace. Meanwhile, we know that this reducibility can be temporary, sometimes difficult to evaluate due to the three-dimensional and multi-factorial character of the deformity. The factors, that can affect the reducibility of the curves are: type of the curve, age and biological status of the child, conception of the brace and the brace type, and the severity of the deformation. This list does not include the probably variable severity of the cause of the disease, which at the moment rests impossible to evaluate. Therefore, what conclusions about the prognosis can be drawn from the obtained percentage of the correction in the brace?

According to OLAFSSON (4), when the percentage of the initial or acute correction of the Cobb angle at the time of Boston brace fitting exceeds 50%, it is highly probable to obtain in 2.6 years in average after the end of the treatment, a real mean correction of 7.2 degrees. Similar findings have been presented after studies concerning the Lyonnais brace (5, 6), three-point brace (7, 8), Milwaukee brace (9, 10, 11, 12) and Chenau Münster brace (13) with a follow-up varying between 1 and 12 years. Doesn't this initial reducibility in the brace constitute a prognostic reference regardless the type of the used brace? That is what we

wanted to verify during this study, realised on the patients with progressive idiopathic scoliosis that we treat with a dynamic corrective brace named SpineCor.

## **MATERIALS AND METHODS**

This is a prospective study, which includes 99 scoliosis patients, for whom any cause of the anomaly was not identified, and therefore they were diagnosed with idiopathic scoliosis. The mean age at the beginning of the treatment was 12.6 years (from 8.5 to 16.5), for 88 girls and 11 boys. The mean initial or pre-therapeutic Cobb angle was 29 degrees. The indication for the therapy was established by means of a demonstrated increase of the Cobb angle of at least 5 degrees, particularly for the curves less than 30 degrees, or by a revealed high risk of progression: Cobb angle  $>20^{\circ}$ , immature patient, high growth potential (14), major postural deformation with a prominence exceeding 7 degrees (measured with scoliometer) (15). This group of factors are frequently found in families, when close relative(s) was(ere) operated for severe idiopathic scoliosis, and where the detection (sometimes effectuated by the family itself) was early.

The dynamic corrective brace SpineCor was used. It is a non-rigid harness that was developed and modified at Saint-Justine Hospital from 1990 to 1993. It is composed of a pelvic base, a low girdle with 3 soft thermo-shaped plastic parts, which is stabilised by 2 thigh bands and 2 crotch bands, a cotton bolero and 4 elastic bands of different lengths (20cm to 1m) (fig.1). The principle of the treatment is based on the definition of a specific corrective movement for each type of curve. This corrective movement induced by the brace or harness, provides progressive postural changes and favours the dynamic correction of curves during the everyday activities and sportive activities of the child. The goal is to allow a reduction in a progressive way, non-aggressive, without hampering the process of growth of skeletal structures, while favouring the acquisition of a more adequate muscular balance. The prescribed duration of wearing is 20 hours out of 24 during rapid growth periods and 10 to 12 hours of daytime wearing during slow growth periods. The weaning from the brace takes place in the vicinity of the bone maturity, either at Risser 4 or after two years of regular menses.

All the patients were followed by the same doctor, in the standardised manner in regards of the same selection criteria, classification, way of fitting and computerised data acquisition. The reported results are based uniquely on the frontal Cobb angle measurement, even though a complete evaluation of the results in the clinic involves clinical, postural data and sagittal x-rays.

The initial pre-therapeutic x-ray, which serves as a reference, is systematically taken following the classic method, within a period of a maximum 1 month before the brace fitting. The following x-ray controls are always administered with the brace following the same schema: the first control at the day of the fitting, then 3 months later, then every 5 months in average until the weaning. After the end of the treatment, the controls are carried on in a rhythm once in 6 months to 2 years depending on the age of the child, until the age of 20 years at minimum. At least one lateral x-ray is required at the beginning, and then once a year. The x-rays are measured by the doctor, the radiologist and a computer technician, considering that these are digital x-rays (the irradiation is half as much as at standard x-ray (16)). Every time the frontal and lateral x-ray are prescribed, they are taken on a turning platform (16) in order to avoid a movement of the child between the two, thus allowing to reconstruct a 3-dimentional image of the spine. The latter is useful in evaluating the three-dimensional aspect of the changes induced by the brace and the changes after the end of the brace treatment.

Considering that this non-rigid brace induces a progressive reduction, the reducibility index is defined as a percentage constituted by the difference between the Cobb angle measured after 3 months of the treatment and the initial, or pre-therapeutic Cobb angle, divided by the initial Cobb angle:

$$\frac{(\text{Initial Cobb} - \text{Cobb at 3 months}) \times 100}{\text{Initial Cobb}}$$

Two series of results are presented. The first series groups together 24 patients (13 having the initial Cobb angle under 30 degrees and 11 over 30 degrees), first prospective cohort, where the follow-up constitutes

an average of 16 months after the end of the brace treatment. This first group allows to value the reducibility index compared with the result after the end of the treatment, when the initial Cobb angle is under or over 30 degrees. The second series consists of 99 patients in total and is divided into two sub-groups: first sub-group: 61 patients (9 boys and 55 girls) with a mean age of 12.3 years, with initial Cobb angle inferior to 30 degrees (mean 23 degrees); second sub-group: 38 patients (2 boys, 36 girls) with a mean age 13 years, with the Cobb angle greater than 30 degrees (mean 39 degrees). The second group permits us to study the value of the reducibility index in relation to the severity of the initial pre-therapeutic Cobb angle and whether this reducibility rests or not with time. Note that there is a division into groups by the 30° value of the Cobb angle according to personal observations and a number of published studies (18, 19, 14, 21, 22, 23 24, 25, 26, 27, 28, 29). These studies demonstrate the well-founded character of this division in the analysis of the results of the studies concerning idiopathic scoliosis.

## **RESULTS**

For the first series of 24 patients (fig. 2), we found that the mean reducibility index is situated at 29% with a standard deviation (SD) of 21% for a significant mean decrease of the Cobb angle of 8.3°, SD = 8.3° (Table 1). At the end of the treatment, the Cobb angle decreased in average by 24% (mean: 6.2°, SD: 9.6°,  $p < 0.01$ ), none of these patients deteriorated in a notable manner. The eleven patients, which have been followed for two years after the end of the brace treatment, as a whole still demonstrated a significant reduction of near 20% (mean: 7.5°, SD: 8.8°). Evidently, the reducibility index at the beginning of the treatment is not equal to the post-treatment correction, there exists a progressive loss in the reduction during the principal growth period of the adolescent.

For the second series that is composed from 99 treated patients altogether, we discover the same type of global evolution (Table 2). After 3 months of wearing the brace, it is possible to notice a significant decrease of the Cobb angle for 8.5° in average (SD: 6.0°). These patients demonstrated at the end of this study a significant decrease of the Cobb angle for 8° (SD: 9.0°). This correction seems to persist with time

since there is no significant difference between the figures at 3 months and the most recent figures. Meanwhile, there exists a difference in the evolution depending on whether the treatment has been started for an initial curve of less than 30 degrees (fig.3) or more than 30 degrees (fig.4). Effectively, although the amplitude of the Cobb angle correction is similar for the two groups, the proportion of this correction in reference to the initial Cobb angle is significantly higher in the group with initial angle under or equal to 30 degrees. This difference is significant after 3 months of the brace treatment as well as at the end of this study (Table 2). On the other side, regardless the pre-therapeutic Cobb angle, the analysis of the results reveals a difference in the evolution in the brace that allows to distinguish two very different sub-populations. This distinction reveals that 85% of the patients maintain or increase with time the percentage of reduction in the brace noted at the third month of the treatment, while the growth velocity increases (fig. 3 and 4, blue lines). On the other hand, 15% of the patients progressively lose this reduction during the same period (fig. 3 and 4, red lines). This observation is more evident in the group with initial Cobb angle under or equal to 30 degrees (fig. 3).

We can also note that the reducibility index of the 15% of treated patients, for whom the reducibility percentage diminishes during the growth spurt, is very low right away and does not exceed 20%.

An examination of two particular cases that represent the two sub-populations with obviously different prognosis will assert in highlighting the results reported by the graphics.

The first observation is a 10-year old girl, non-menstruating, Risser 0, at the moment of the brace fitting. Her right thoracic idiopathic scoliosis with major postural deformation (prominence 11 degrees, frontal shift to the right 3cm), was measured at 36 degrees (fig. 5) after a 1-year evolution of the curve initially detected at 21 degree (fig. 5). Relatively stable during 6 months, she rapidly aggravated during the following 6 months when her growth accelerated (4 to 5mm per month for the standing height) while no particular risk factor could be detected. Please note that the curve is relatively long, with slightly deformed or wedged vertebrae. The thoracic sagittal curve is flattened clinically and radiologically, resulting in moderate hypokyphosis, which is evident on the three-dimensional reconstruction (fig.6). The brace, prescribed

because of this fast aggravation, permits to obtain a progressive reduction, from 36 to 21 degrees on the day of the fitting, to 16 degrees at the third month of wearing the brace, and to 4 degrees after 6 months in the brace. The latter result has been stable up to this moment. The obtained reduction is three-dimensional (30) as demonstrates fig. 7. Except for this curve being particularly long, this observation is representative of what we observe in 80% of the patients, particularly when the treatment was started for the curves under 30 degrees, or over 30 degrees but with a recent aggravation and young and immature patients without major risk factors.

The second case is a 10-year old girl, non-menstruating, Risser 0, at the moment of the brace fitting. Her scoliosis is right thoracic, measured at 30 degrees (fig. 8). The postural deformation is moderate (right prominence of 9 degrees, frontal shift to the right 0.5cm). The family history affirms an elevated risk of progression, two older sisters being operated for the severe scolioses of the same type. The third older sister also has a right thoracic curve (20 degrees) which rests stable without treatment, however she has a mesomorph morphotype and a relatively slow and progressive growth, opposite to the other three sisters that are ectomorph and have rapid growth spurts. The x-ray of the youngest sister demonstrates a curve of 30 degrees (fig.8), relatively short, the apexian vertebrae look very deformed and wedged, which was confirmed by the 3D scanner reconstruction (fig. 9) (the scanner also permits to exclude any pronounced radiculo-medullar anomalies). The brace was administered without waiting for an additional aggravation. The maximal obtained reducibility was 7%, superimposable on the result of bending-test, that indicates a rigid curve. After two years and six months of wearing the brace and a significant growth spurt (8mm per month for the standing height) the Cobb angle in the brace is 34 degrees, 36 degrees without brace, that indicates a poor prognosis. This case is demonstrative regarding less than 20% of our patients for whom the goal is a stabilisation around the initial Cobb angle and for a few of them, an uncontrollable aggravation will emerge a necessity of surgical treatment.



## **DISCUSSION**

The prospective study that was started in 1994 is ongoing. However, this study aims at demonstrating the importance of the initial results. The protocol was prepared meticulously and the follow-up is conducted with a lot of care in regards the gathering of clinical data, as well as the postural and x-ray data. This allows us to study indexes which are so precise as the reducibility index. It is already realised that the global presentation of the results conceals important data revealed by the case studies and information on more homogeneous populations. However, the number of the patients and insufficient time after the end of the treatment does not allow the presentation of more detailed results. Whereas the reducibility index is proposed as a prognostic factor to consider, limitations are also suggested and justified.

If the treated patients are divided in two groups depending on whether the Cobb angle is under or over 30 degrees, a clear difference emerges in terms of the reducibility index value and the maintenance of the reducibility with time. The fact that scoliosis with a small angle is more reducible (even independently of the age and to a certain extent of the maturation stage) does not defer our comprehension of the pathology. On the other hand, the fact that a majority of these patients will have their curve(s) diminished at the time when the growth spurt starts, is unexpected. It looks like a sufficient reduction of the curves under 30 degrees reverses the negative impact of the growth and instead favours an additional reduction of the curves. It was also found that the non-rigid dynamic corrective brace permits to take an advantage of a

certain flexibility of the curves, which accompanies growth spurts, which were thoroughly detected. Every time the patient comes to the clinic, the brace is adopted according to the growth and maturation, as well as the curve evolution, which in this case means a progressive reduction. Conversely, we observe that approximately 15% of the curves under 30 degrees are non-reducible or reducible very slightly, even in young and immature patients. In this case, the factor of growth remains negative. Therefore, the presumed goal of the treatment is a stabilisation of the curves close to the initial amplitudes. And it is also the group of patients where the real failures of the treatment occur, in spite of early diagnosis, close follow-up and a duly verified compliance. When we have to opt for an operation, that is in less than 6% of the cases, the doctor-patient relationship must be well established in order to control the most difficult event in this disease. When it is possible to forecast this situation due to the reducibility index value and its changes with time, it is possible to establish early the individual prognosis as well as prepare the child and his family, or redirect the treatment earlier.

Nevertheless, it appears very advantageous to treat the idiopathic scoliosis before it achieves 30 degrees. The treatment can be less aggressive (non-rigid brace) and the results can be superior in terms of the Cobb angle. The results are also better in terms of the posture and muscular function, which is at least preserved or most often improved due to the maintenance of the appropriate spine dynamics. Taking into account, that between 20 and 30 degrees, from 60 to 70% of idiopathic scolioses aggravate (31, 14), it seems to be even more important to treat scolioses at small angles. The early detection allows monitoring and evaluation of the risk factors (curve of growth, family investigation, complimentary tests when necessary) and provides the time to ascertain the reality of the risk of progression without affecting the post-therapeutic result.

The presented results, concerning the evolution of the reducibility during and after the treatment, are superimposable on those reported in the literature (21). It seems evident that the more the scoliotic curve is reduced during the brace treatment, the better are the chances of stabilisation and even correction (maintenance of the reduction after the end of the brace treatment). However, all the authors (5, 6, 7, 8, 9,

10, 11, 12, 13, 21) notice a difficulty to maintain the obtained reduction during the periods of rapid growth. It is true even for particularly aggressive braces with preliminary casting, like the Lyonnais brace (5, 6). In order to be more specific about the individual prognosis, it seems to be important to consider in addition to the reference reducibility, an impact of the factor of growth during the growth spurt (32, 33, 34, 35, 36, 37, 38, 39, 40) on the percentage of the reduction obtained in the brace. The growth spurts are identified by means of measuring the standing height or better the height of the back.

Concerning the angular loss frequently found after the end of the treatment while the growth is practically finished, a few factors must be taken into account. This angular loss is no longer in relation with the growth, but mostly with the mechanical factors, including the bone deformations of the vertebrae, the condition of the disks, muscular imbalance and the global tonus. The vertebral deformation is apparently a factor of the rigidity of the curves, and also favours a progressive collapse of the curves by default of the induced intra- and extra-spinal forces (41). By means of scanner three-dimensional reconstruction of the vertebrae at the apical zone in a number of idiopathic scolioses of high risk, we found that these deformations appear early and affect a mean of two vertebrae in the vicinity of the apex.

These significant three-dimensional deformations can be pronounced in the 30-degree curve of the 10-year-old patient presented in the fig.8, they are barely less severe than those in a 60-degree thoracic curve of the same type in a 15-year-old pre-operative patient (fig. 10). The severity of the vertebral deformations deserves a better evaluation and can constitute a prognostic index complementary to the reducibility index. Thus, it could provide a better comprehension of the poor reducibility of certain curves, the severe impact of growth on these curves and define early the limits of the brace treatment. This hypothesis was already expressed following an animal study (42), where the findings strongly suggested the earliness of the vertebral deformations and their impact on this pathology.

Therefore, the reducibility index can not solely constitute a perfectly reliable prognostic criterion. Nevertheless, when it exceeds 30%, and all the more when it exceeds 50% as reported by Olafsson (4),

the reducibility index is a favourable prognostic index independent of the type of the used brace (provided that the compliance is good). We consider that the prognosis can be more accurate, when considering the impact of the growth on the reducibility index and exploring the extent of the vertebral deformations upon the time the diagnosis is established.

### **CONCLUSION**

The reducibility of the curves in idiopathic scoliosis, when established at the beginning of the brace treatment, constitutes a valid global prognostic index. But in order to apply it individually, it is important to calculate it correctly (while using two x-rays without and with the brace, separated with a limited period of time). It is also necessary to take into account the influence of the growth acceleration on the curve evolution in the brace, and the severity of the vertebral deformations at the time of diagnosis.

In corollary, a distinction of the terms must be done between the *reducibility* and *correction* that can not be used in the same circumstances. The reducibility means a possibility, and therefore does not have a definitive character, and can not be substituted by the correction, obtained at the end of the treatment. The correction constitutes a more definitive notion, provided that the maturation eliminates the most prejudicial factor in the evolution of scoliotic curves.

Along with the first conclusion, we consider that the distinct superiority of the outcomes of the brace treatment in the patients, for whom the treatment has been started under 30 degrees, points to the advantages of an early treatment of idiopathic scolioses.

Lastly, with 5 year's of experience using the dynamic corrective brace SpineCor proves our hypothesis, that the efficacy or the failure of the brace treatment does not depend on the rigidity or aggressiveness of the used brace, but on a well-conducted treatment and above all on the severity of the cause. The latter rests unfortunately unknown and therefore non-assessable.

## **REFERENCES**

1. Winter R.B. - The pendulum has swung too far. Orthopedic Clinics of North America 1994; 25 : 195-205.
2. Rowe D.E., Bernstein S.M., Riddick M.F., Adler F., Emans J.B., Gardner-Bonneau D. - A meta-analysis of the efficacy of non-operative treatments for idiopathic scoliosis. JBJS 1997; 79-A : 664-674.
3. Schuffelbarger H.L., Keiser R.P., King W. - Nonoperative treatment of idiopathic scoliosis : a 10 years study. Orthop. Trans. 1983; 7 : 11-13.
4. Olafsson Y., Saraste H., Soderlund V., Hoffsten M. - Boston brace in the treatment of idiopathic scoliosis. J Pediatr Orthop 1995; 15 : 524-527.
5. Mauroy J.C. De, Stagnara P. - Résultats à long terme du traitement orthopédique lyonnais des scolioses inférieurs à 50°. Journées de la scoliose, Lyon 1979.
6. Michel C.R., Caton J., Michel F. - Devenir à long terme des scolioses idiopathiques ayant subi un traitement orthopédique lyonnais. Rev. Chir. Orthop. 1987; 73 suppl. II : 134-136.
7. Caton J., Michel C.R., Fiquet A., Jouvinroux P. et coll. - Le traitement orthopédique des scolioses lombaires et thoracolombaires par l'orthèse rachidienne à 3 valves. Une expérience de 17 ans et de plus de 800 orthèses. Rev. Chir. Orthop. 1987; 73 suppl. II : 138-142.
8. Michel C.R., Caton J., Allegre G. Et M. - Place de l'orthèse rachidienne à 4 valves dans le traitement orthopédique des scolioses (à propos de plus de 700 cas et de plus de 10 ans d'expérience). Rev. Chir. Orthop. 1983; 69 suppl. 2 : 135-140.
9. Mellencamp D.D., Blount W.P., Anderson A.J. - Milwaukee brace treatment of idiopathic scoliosis : late results. Clin. Orthop. 1977; 126 : 47-57.
10. Carr W.A., Moe J.H., Winter R.B., Lonstein J.E. - Treatment of idiopathic scoliosis in the Milwaukee brace. Long-term results. JBJS 1980; 62-A : 599-612.
11. Salanova C. - Late results of Milwaukee brace treatment of idiopathic scoliosis. Orthop. Trans. 1986; 10 : 2-5.
12. Edmonson A., Smith G.R. - Long-term follow-up study of Milwaukee brace treatment in patients with idiopathic scoliosis. Orthop. Trans. 1983; 7 : 10-11.
13. Cheneau J. - L'orthèse de Munster. Ann. Méd. Phys. 1981; 24 :377-391
14. Lonstein J. E., Carlson J. M. - The prediction of curve progression in untreated idopathic scoliosis during growth. JBJS 1984; 66-A (7) : 1061-1071.
15. Duval-Beaupère G., Lamireault T. - Scoliosis at less then 30°. Properties of the evolutivity (risk of progression). Spine 1985; 10 : 421-424.
16. Roy M., Boutard A., Labelle H. - La radiologie numérique permet-elle vraiment de diminuer l'exposition aux radiations chez les adolescents avec scoliose idiopathique? Communication Société de la scoliose du Québec 1997.

17. Aubin C. É., Descrimes J. L., Dansereau J., Skalli W., Lavaste F., Labelle H. - Modélisation géométrique du rachis et du thorax pour l'analyse biomécanique par éléments finis des déformations scoliotiques. *Ann Chir* 1995 ; 49 : 749-761
18. Stagnara P. Journée de la scoliose Lyon 1979; Bosc Frères, Lyon, 1979.
19. Perdriolle R., Vidal J. - Thoracic idiopathic scoliosis curve. Evolution and prognosis. *Spine* 1985; 10 : 785-791.
20. Berard J., Kohler R., Dimeglio A. - Scoliose idiopathique. Editeur Saurapms Médical 1997.
21. Guillaumat M., Lebard J.P., Khouri N., Tassin J.L. - Traitement de la scoliose idiopathique en période de croissance. *Encycl Med Chir app locomoteur* 1991; 15 : 1-18.
22. Fustier T. - Evolution spontanée des scolioses idiopathiques de moins de 50° en période de croissance. Thèse Méd 1980.
23. Duriez J. - Évolution de la scoliose idiopathique chez l'adulte. *Acta Orthop Belg* 1967; 33 : 547-551.
24. Nachemson A. - End results of untreated idiopathic scoliosis in later life. Sicot ed., Mexico 1969;
25. Nilsson U., Lundgren K.D. - Long-term prognosis in idiopathic scoliosis. *Acta Orthop Scand* 1968; 39 : 456-465.
26. Collis D.K., Ponseti I.V. - Long-term follow-up of patients with idiopathic scoliosis non treated surgically. *J.Bone Joint Surg* 1969; 51-A : 425-445.
27. Fowles J.V., Drummond D. L'Écuyer S., Roy L., Kassab M.T. - Untreated scoliosis in the adult. *Clin Orthop* 1978; 134 : 212-217.
28. Peyer J. - La scoliose de l'adulte. *Z Orthop* 1975; 113 : 577-582.
29. Briard J.L., Jegou D., Cauchoix J. - Adult lumbar scoliosis. *Spine* 1979; 4 : 526-532.
30. Dansereau J., Beauchamp A., De Guise J. A., Labelle H. - Three dimensional reconstruction of the spine and rib cage from stereoradiographic and imaging techniques. Résumé de la 16 e conférence de la Société Canadienne de Génie Mécanique, 1990 ; 2 : 61-64.
31. Bunnell W.P. - The natural history of idiopathic scoliosis. *Clin Orthop* 1988; 229 : 20-24.
32. Duval-Beaupère G., Dubousset J., Queneau P., Grossiord A. - Pour une théorie unique de l'évolutions des scolioses. *Press Méd* 1970; 88 : 1141-1146.
33. Dimeglio A., Bonnel F. - Le rachis en croissance. Springer-Verlag 1990.
34. Dimeglio A.- La croissance en orthopédie. Sauramps Médical 1987.
35. Stagnara P. - Les déformations du rachis, scolioses, cyphoses. 1 vol. Masson et Cie. Éd., Paris 1985; 452 p.
36. Ponseti I., Friedman B. - Prognosis in idiopathic scoliosis. *J.Bone Joint Surg* 1950; 32A : 381-395.
37. Cotrel Y. - Les types de scolioses. *J. Kinésithér* 1959; 7 : 2-12.

38. Loncar-Dusek M., Pecina M., Prebeg Z. – A longitudinal study of growth velocity and development of secondary gender characteristics versus onset of idiopathic scoliosis. *Clinical Orthopaedics and related research* 1991; 270 : 278-282.
39. Tanner J.M. – Growth at adolescence. Blackwell Scientific Publications ed., Oxford 2<sup>e</sup> ed 1962.
40. Willmer S. – The proportion of legs trunk in girls with idiopathic structure scoliosis. *Acta Orthop Scan* 1975; 46: 84-99.
41. White A. A., Panjabi M.M. -Clinical biomechanics of the spine. 2nd ed. Lippincott, Philadelphia. 1990; 128-168.
42. Coillard C., Rivard C.H. - Vertebral deformities and scoliosis. *Eur Spine J* 1996; 5 : 91-100.



## **LEGENDS**

Fig 1 : Dynamic Corrective Brace or SpineCor : anterior and posterior views, isolated from the skin by an undergarment (body). The principal components are: a pelvic base (stabilised by two thigh bands and 2 crotch bands), a cotton bolero and 4 corrective elastic bands.

Fig. 2 : Evolution of the angle of Cobb in reference to the initial Cobb angle of 24 patients where treatment was terminated in conformity to the therapists indication with an average of 16 months. The values of Cobb angle are normalised in reference to the initial Cobb angle (corresponding to 100% for all of the patients at the beginning of treatment). The data presented in the figure are expressed in percent of the initial Cobb angle. The temporal scale is also normalised in reference to the length of the treatment for each patient (at the end of treatment, each patient achieved 100% of their length of treatment). During treatment, the angle of Cobb is measured on the radiographs obtained with the brace. After the termination of treatment, the temporal scale is in months, and the radiographs are obtained without brace.

Fig. 3 : Evolution of the Cobb angle in reference to the initial Cobb angle of 61 patients for whom the treatment was started when the Cobb angle was inferior to 30 degrees (mean 23 degrees). The values of Cobb angle are normalised in reference to the initial Cobb angle (corresponding to 100 % for all of the patients at the beginning of treatment). The data presented in the figure are therefore expressed in percentage of the initial Cobb angle. Analysis of the evolution of the Cobb angle during treatment identifies the existence of two sub-groups of patients which evolve differently, when the growth velocity increases. Ten patients (red line), worsened despite a well-followed treatment, the Cobb angle surpassed the initial Cobb angle. At the same time, for the 51 other patients (blue line), the treatment allowed a gradual achievement of the obtained reduction.

Fig. 4. : Evolution of the Cobb angle in reference to the initial Cobb angle for 38 patients, in which the treatment was started when the Cobb angle was greater than 30 degrees (mean 39 degrees). The values of Cobb angle are normalised in reference to the initial Cobb angle (corresponding to 100 % for all of the

patients at the beginning of treatment). The data presented in the figure are therefore expressed in percentage of the initial Cobb angle. Analysis of the evolution of the Cobb angle during treatment identifies the existence of two sub-groups of patients which evolve differently, when the growth velocity increases. Six patients (red line) worsened, despite a well followed treatment, the Cobb angle tends to surpass the initial Cobb angle. At the same time for the 32 other patients (blue line), the treatment allowed a gradual achievement of the obtained reduction.

Fig. 5 : Radiographs of a patient aged 10 years, demonstrated an aggravation of the long right thoracic curve, the angle of Cobb went from 21 to 36 degrees within a period of one year.

Fig. 6 : Three dimensional reconstruction (3D) from the sagittal and frontal radiographs of the same patient presented in figure 5, taken immediately pre-therapeutically. The angle of Cobb is 36 degrees and the kyphosis is measured at 16 degrees.

Fig. 7 : Three dimensional reconstruction in reference to radiography of the sagittal and frontal views after 7 months of treatment, of the same patient presented in figures 5 and 6, demonstrating the 3D aspect of the obtained reduction.

Fig. 8 : Radiographs of a patient aged 10 years, showing the frontal and sagittal views of this right thoracic idiopathic scoliosis of 30 degrees, short, with a pronounced cuneiformisation of the apexian vertebrae and a kyphosis abnormally decreased.

Fig. 9 : 3D scanner reconstruction of the eighth thoracic vertebra (apex) of the same patient as figure 8, who has a right thoracic curve of 30 degrees, showing the 3D aspect of the deformation which is representative of the deformations regularly observed in the idiopathic curves. Note in particular the "arc of a circle" deformation in the apical view and the difference in height between the 2 posterolateral parts of this

same vertebra, which is evident by the decreased distance between the two costal heads, highly visible, independent of the view of incidence chosen.

Fig. 10 : 3D scanner reconstruction of the eighth thoracic vertebra (apex) of a patient aged 15 years with a right thoracic curve of 60 degrees of the same type as that of fig. 8. Note the 3D aspect of the deformation of this vertebra, comparable to that presented in fig. 9. Note in particular the "arc of circle" deformation in the apical view, previously described by White and Panjabi (19) and the difference in the height between the two postero-lateral parts of the same vertebra. This is evident by the decreased distance between the two costal heads, highly visible, independent of the incidence view chosen.

Table1. Cobb angle evolution of patients for which the brace treatment has ended (n = 24).

Visit n=24	Cobb angle
Initial	30.9° (8.6°)
After 3 months of wearing the brace*	22.5° (9.8°)
Correction	8.3° (8.3°)
At the end of the treatment *	24.7° (13.4°)
Correction	6.2° (9.6°)
24 months after the end of the treatment (n = 12)	23.6° (10.4°)
Correction	7.5° (8.8°)

\* p < 0.01, significant difference from the initial visit.

Table 2. Cobb angle measured before the treatment, after three months of brace treatment and at the end of the study for the 99 patients in treatment.

	Initial Cobb ≤ 30° n = 61 Mean (SD)	Initial Cobb > 30° n = 38 Mean (SD)	All the patients (n = 99) Mean (SD)
Initial Cobb angle *	23.2° (4.6°)	39.1° (6.9°)	29.3° (9.5°)
Cobb angle at 3 months *	14.6° (6.8°)	30.9° (8.5°)	20.8° (10.9°)
Correction <sup>ns</sup>	8.7° (5.3°)	8.1° (7.1°)	8.5° (6.0°)
% of correction *	38.6 (23.8)	20.6 (16.8)	31.7 (23.0)
Cobb angle at the end *	14.7° (10.3°)	32.0° (10.4°)	21.4° (13.3°)
Correction <sup>ns</sup>	8.5° (8.5°)	7.1° (9.9°)	8.0° (9.0°)
% of correction *	39.5 (39.0)	17.5° (25.3°)	31.0° (35.9°)

\* p < 0.01, significant difference between two groups of patients.

<sup>ns</sup>  $p > 0.01$ , the difference is not statistically significant.

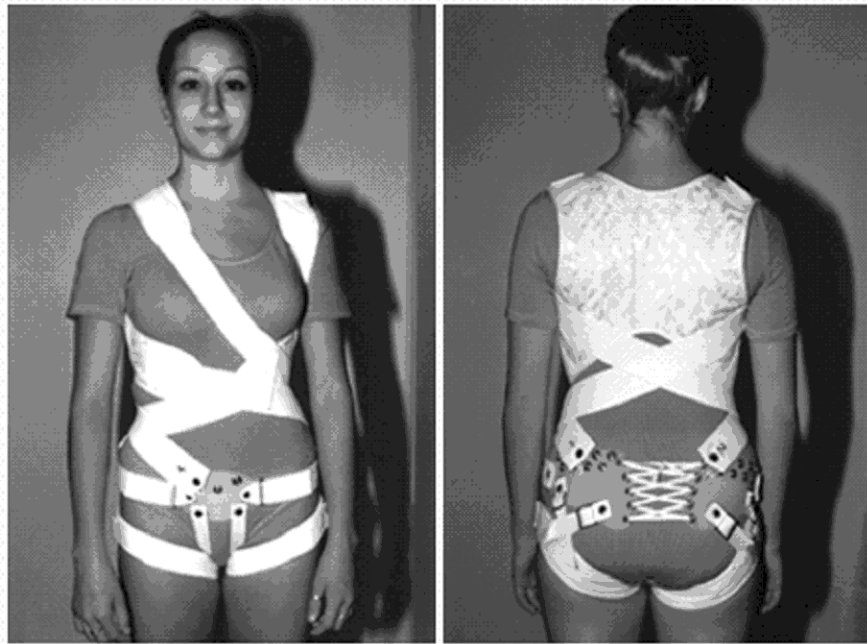


Fig.1 : SpineCor: anterior and posterior view

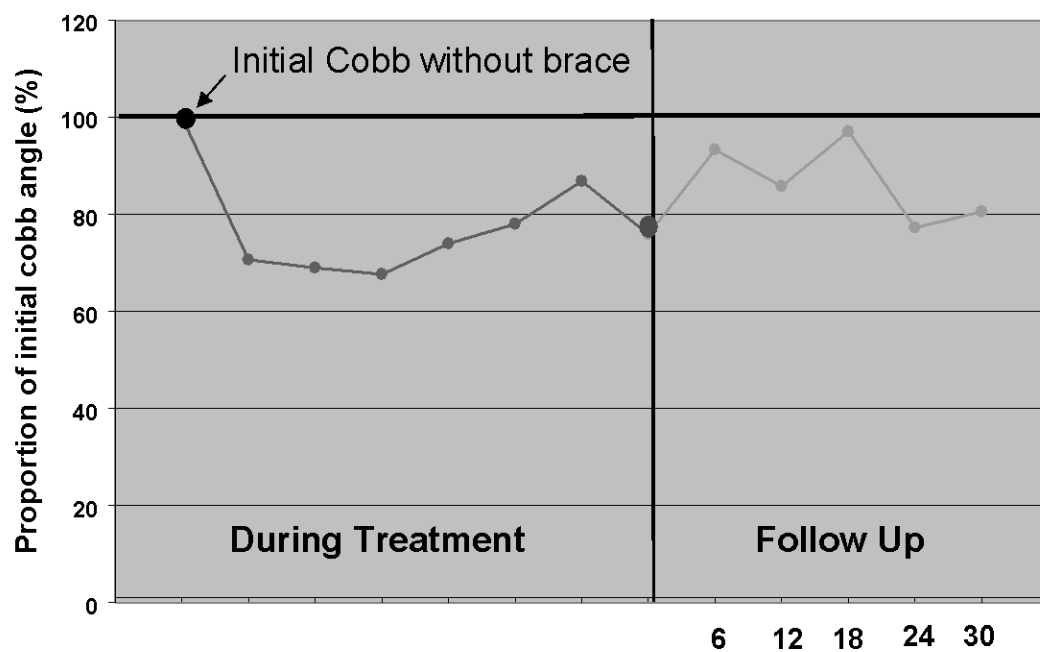


Fig 2 : Mean Cobb angle variation : pre and post treatment.

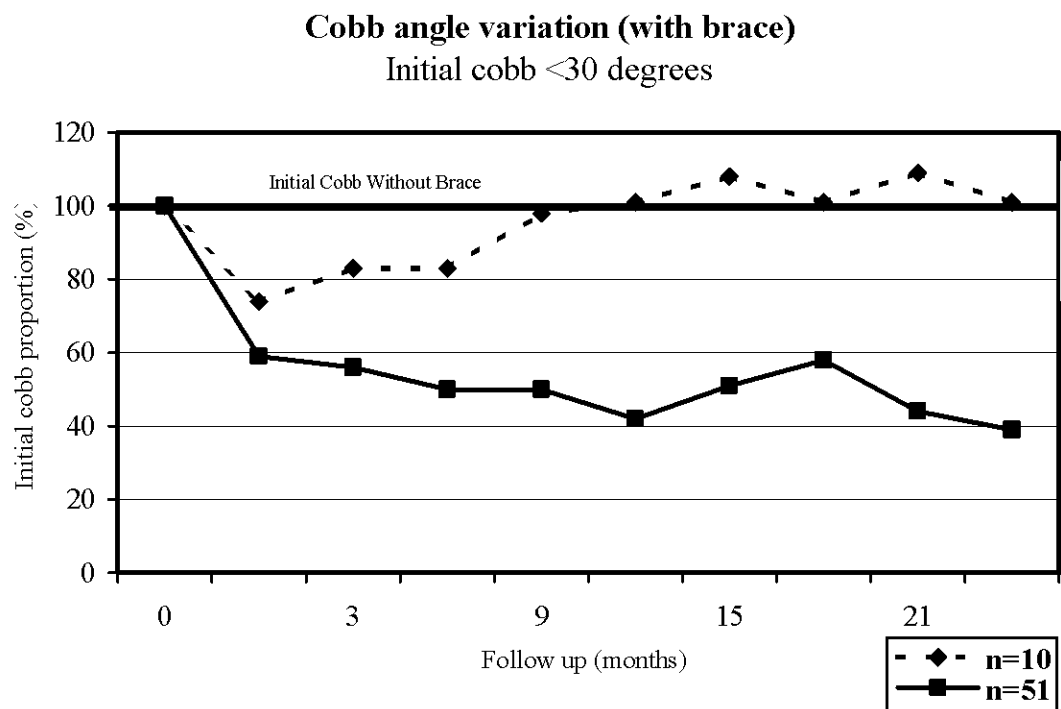


Fig 3 : Mean Cobb angle variation : initial Cobb  $\leq 30^\circ$ .

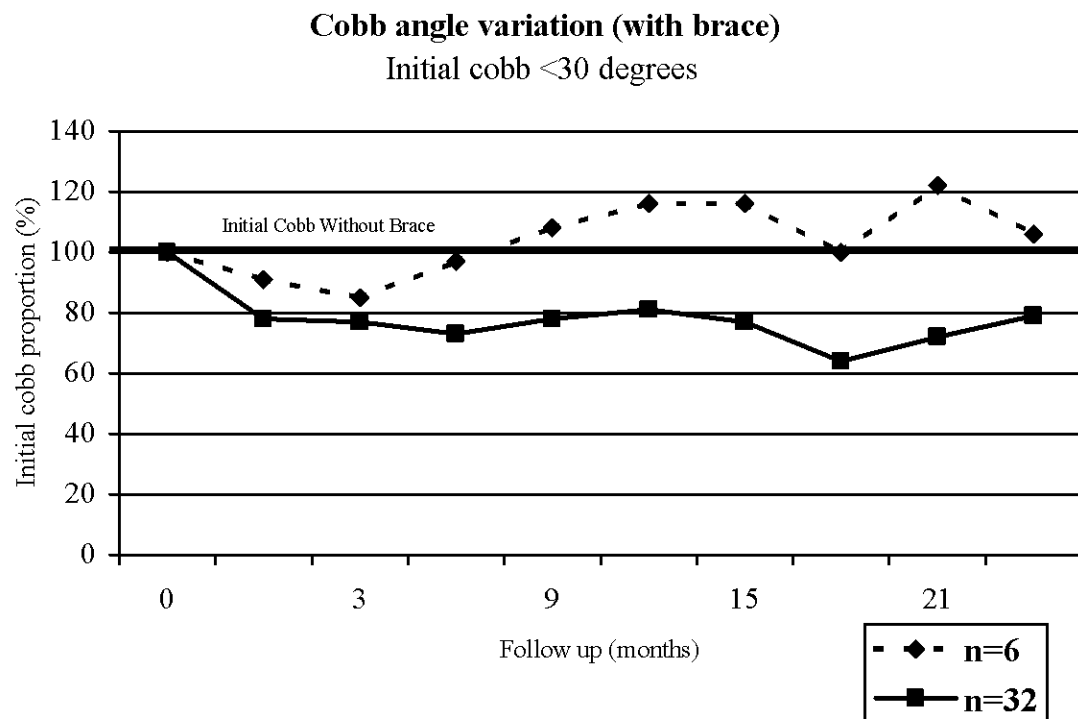


Fig 4 : Mean Cobb angle variation : initial Cobb  $> 30^\circ$ .

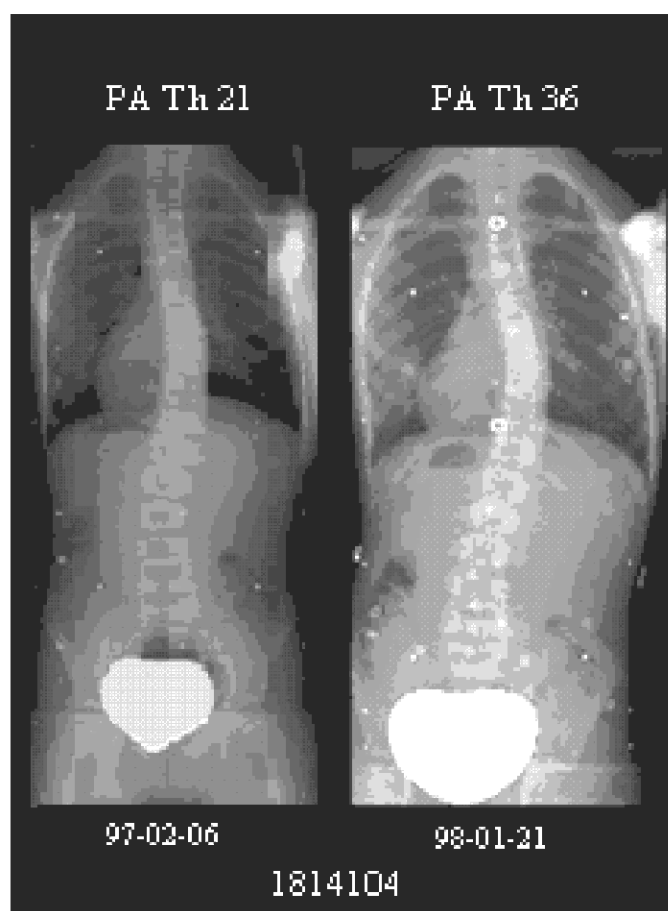


Fig.5 : Case1, aggravation from 21 to 36 degrees.

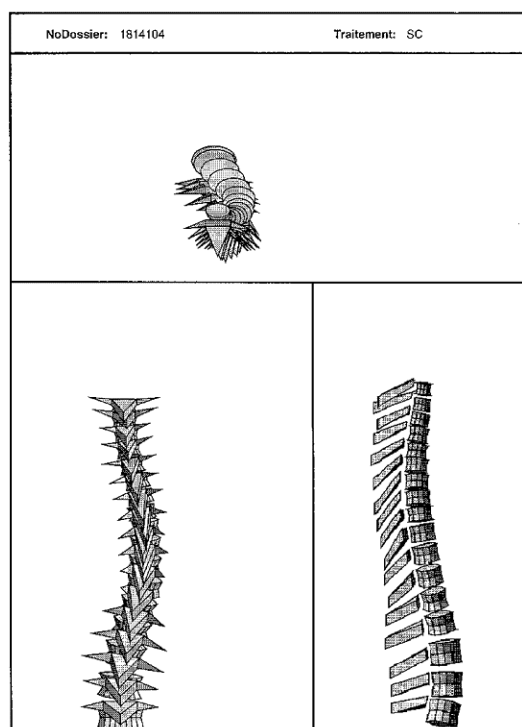


Fig. 6 : Case1, 3D reconstruction before treatment

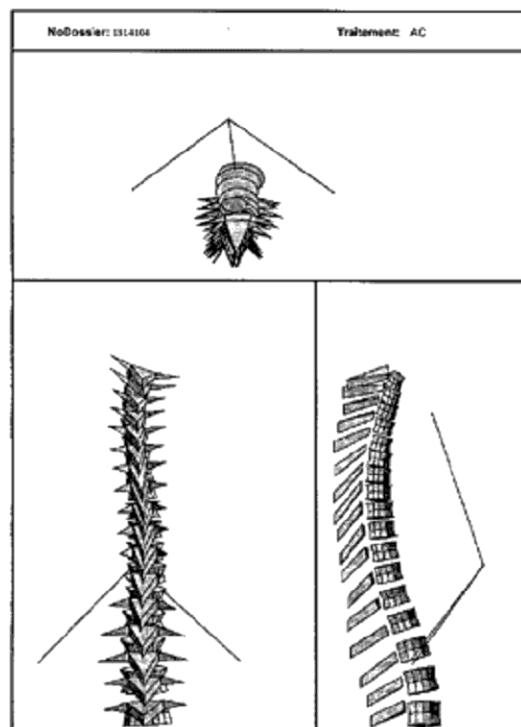
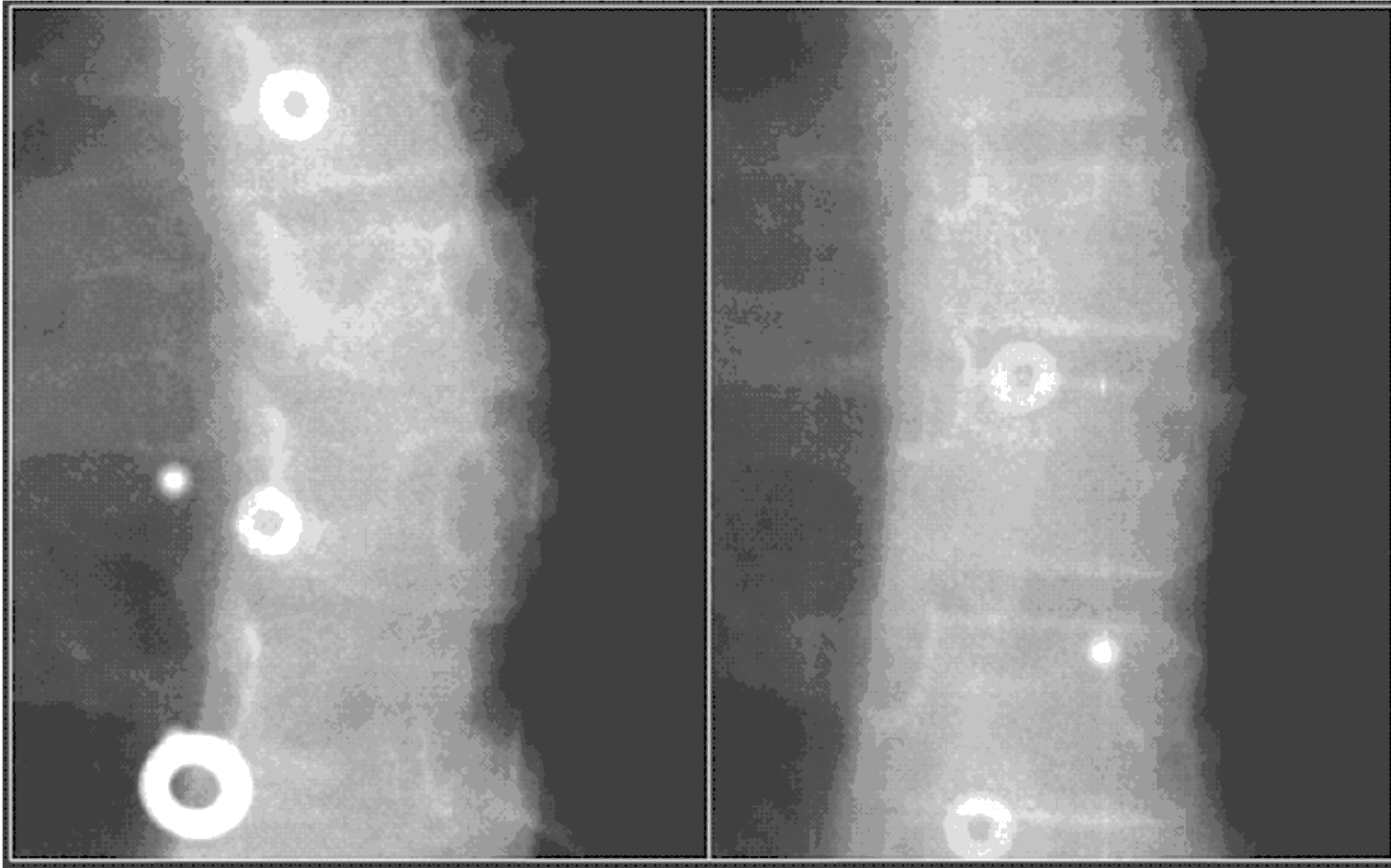


Fig. 7 : Case1, 3D reconstruction after 7 months of treatment







Bone remodelling of the vertebrae at the apex of the right thoracic curve (case 1), which went from 36 to 2 degrees of Cobb angle after 17 months of treatment with SpineCor.